

HEMOLYTIC ANEMIA ASSOCIATED WITH METHIMAZOLE TREATMENT FOR GRAVES' DISEASE

RALUCA TRIFĂNESCU^{1,2}, MĂDĂLINA VASILICA³, MARA CARȘOTE^{1,2}, DUMITRU FERECHE^{4*}, CĂTĂLINA POIANĂ^{1,2}

¹ Department of Endocrinology, "Carol Davila" University of Medicine and Pharmacy, Bucharest, Romania

² "C.I. Parhon" Institute of Endocrinology, Bucharest, Romania

³ Fundeni Hospital, Bucharest, Romania

⁴ Department of Physiology, "Carol Davila" University of Medicine and Pharmacy, Bucharest, Romania

* corresponding author: dferec@yahoo.com

Abstract

Methimazole is the most frequently used antithyroid drug for the treatment of thyrotoxicosis in Europe. Haematological side effects of Methimazole such as agranulocytosis, aplastic anaemia and thrombocytopenia are well known, but haemolytic anaemia was very seldom reported.

A 51 years old Caucasian man presented with severe Graves' disease. After 2 weeks of Methimazole treatment (30 mg/day), the patient developed pruritus and arthralgia; biochemical data showed haemolytic anaemia with increased reticulocytes, total and unconjugated bilirubin. Methimazole was replaced by carbimazole and then replaced by lithium carbonate (450 → 600 mg/day), with normalization of thyroid hormones levels. Intravenous glucocorticoids (Methylprednisolone 125 mg/day, 3 days) followed by oral corticosteroids (Prednisone 1 mg/kg bw/day) and folic acid 5 mg/day successfully controlled haemolytic anaemia. Total thyroidectomy was safely performed and the patient had an uneventful recovery.

This is the first case report of haemolytic anaemia associated with Methimazole in Romania. It should be underlined that haemolytic anaemia could be associated with Graves' disease and may be a rare complication associated with methimazole therapy.

Rezumat

Metimazolul este cel mai utilizat antitiroidian de sinteză folosit în tratamentul tirotoxicozei în Europa. Reacțiile adverse hematologice ale antitiroidienelor de sinteză sunt bine cunoscute (agranulocitoză, anemie aplastică, trombocitopenie), dar anemia hemolitică a fost rar descrisă.

Un bărbat caucazian în vârstă de 51 ani s-a prezentat cu boală Graves severă. După 2 săptămâni de tratament cu Metimazol (30 mg/zi), pacientul a dezvoltat prurit și artralgii; datele biochimice au evidențiat anemie hemolitică, cu creșterea reticulocitelor și a bilirubinei totale prin hiperbilirubinemie indirectă. Metimazolul a fost înlocuit cu carbimazol și apoi cu carbonat de litiu (450 → 600 mg/zi), cu normalizarea hormonilor tiroidieni. S-au administrat glucocorticoizi inițial intravenos (Metilprednisolon 125 mg/zi, 3 zile), apoi oral (Prednison 1 mg/kg corp/zi) și acid folic 5 mg/zi cu controlul anemiei hemolitice. S-a realizat cu succes tiroidectomia totală, evoluția pacientului fiind favorabilă.

Acesta este primul caz raportat în România de anemie hemolitică asociată tratamentului cu Metimazol la un pacient cu boală Graves. Trebuie reținut că anemia hemolitică poate apărea ca o complicație rară atât a bolii Graves, cât și a terapiei cu metimazol.

Keywords: methimazole, haemolytic anaemia, thyrotoxicosis.

Introduction

Methimazole treatment was associated both with minor side effects (skin reactions, arthralgia, gastric distress, nausea, sialadenitis, abnormal sense of taste and smell) and important side effects (polyarthrititis, antineutrophil cytoplasmic antibody (ANCA) positive vasculitis, agranulocytosis, immunoallergic hepatitis, cholestasis, hypoglycaemia due to insulin-binding antibodies), that could be life-threatening [6, 23]. Haematological side effects of antithyroid drugs [6, 24], such as agranulocytosis [11, 27], aplastic anaemia [12, 19, 28] and thrombocytopenia are well known [6, 9, 26], but haemolytic anaemia was very seldom reported [25].

In a large cohort of 50,385 patients with Graves' disease, 50 patients developed agranulocytosis and 5 developed pancytopenia [31]. Antithyroid drug treatment duration prior to the onset of agranulocytosis was reported to be approximately 1 to 4 months [31, 33]. Cases with sudden onset after just 6 days treatment [33] as well as cases with onset after 11 years of continuous antithyroid drug treatment [21] were reported.

Bone marrow characteristics in antithyroid drugs-induced agranulocytosis can be classified into type I with reduction or absence of granulocytic precursors and type II with hypercellular bone marrow with dysmaturity of granulocytic cells. Type I was associated with a worse clinical prognosis compared to type II [34]. In isolated cases, antithyroid drugs-induced agranulocytosis was followed by other hematologic diseases, such as multiple myeloma [8].

Antineutrophil cytoplasmic antibody (ANCA)-associated vasculitis was reported both in patients treated with methimazole [36], and propylthiouracil [14].

Materials and Methods

A 51 years old Caucasian man initially presented at "C. I. Parhon" Institute of Endocrinology, Bucharest, Romania, with severe hyperthyroidism due to Graves' disease. There was not a family history of hyperthyroidism or other autoimmune disorders. The patient signed an

informed consent and agreed upon the presentation of scientific data anonymously.

Thyroid Stimulating Hormone (TSH), free thyroxine (FT₄), total thyroxine (TT₄), total triiodothyronine (TT₃) were measured by immunochemiluminescence, thyroid stimulating hormone receptor antibody (TRAb) were measured by microparticle enzyme immunoassay (MEIA).

Results and Discussion

A 51 years old Caucasian man, resident in an iodine-repleted area, initially presented in a tertiary endocrine centre ("C. I. Parhon" National Institute of Endocrinology, Bucharest, Romania) with typical hyperthyroidism symptoms: marked weight loss (40 kg), tremor, heat intolerance, thyroid enlargement. Biochemical data revealed severe hyperthyroidism (TSH < 0.03 mIU/L, FT₄ > 100 pmol/L, TT₃ > 500 ng/dL) due to Graves' disease (TSH Receptor antibodies= 7.62 IU/L). There was no significant exophthalmia (right eye exophthalmometry= 15.5 mm, left eye exophthalmometry= 16 mm, normal motility). Thyroid ultrasound revealed diffuse thyroid enlargement (67 mL), with hypoechoic inhomogeneous pattern and increased vascularisation. Haemoglobin was 14.7 g/dL and alkaline phosphatase slightly increased (149 IU/L).

Antithyroid drugs treatment was initiated (Methimazole 30 mg/day) for a few days in the hospital and was well tolerated; thereafter, treatment was continued in ambulatory. After 2 weeks of Methimazole treatment, the patient presented with pruritus and arthralgias, unresponsive to the replacement of Methimazole with Carbimazole. Clinical exam revealed scleral jaundice, macular rash and liver enlargement without splenomegaly. Patient was hospitalized; biochemical data showed haemolytic anaemia: haemoglobin decreased from 14.7 g/dL (baseline) to 13 g/dL, increased reticulocytes (3.1%), increased total bilirubin (3.62 mg/dL) with increased unconjugated bilirubin (2.82 mg/dL). Alkaline phosphatase was slightly increased (152 IU/L) and both transaminases presented normal levels. Thrombocytes were without the normal limits (165,000/mm³), coagulation tests: international normalized ratio (INR) and activated partial thromboplastin time (APTT) were normal, excluding Evans' syndrome. Sideremia was normal (85.1 µg/dL). Thyrotoxicosis was slightly improved (TT₃=250 ng/dL, TT₄=14.3 µg/dL).

Methimazole initially and thereafter Carbimazole, treatment was stopped and lithium carbonate administration in a dose of 450 → 600 mg/day was initiated, for four weeks, with normalization of thyroid hormones levels (TT₃=183 ng/dL, TT₄=12 µg/dL) and without side effects

(lithaemia= 0.38 → 0.37 mEq/L, no nephrogenic *diabetes insipidus*). TSH and thyroid hormones' evolution during the treatment is presented in Figure 1.

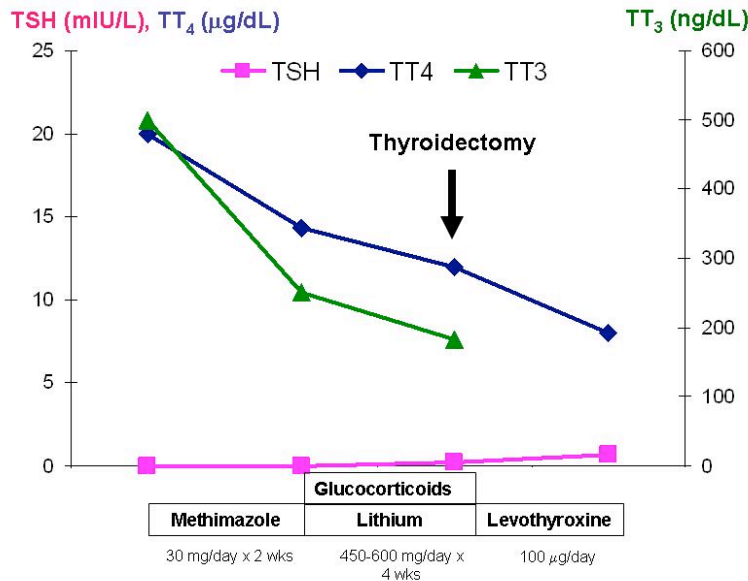


Figure 1.
Evolution of thyroid function during the treatment

For the treatment of haemolytic anaemia, intravenous glucocorticoids (Methylprednisolone 125 mg/day, 3 days) followed by oral corticosteroids (Prednisone 1 mg/kg bw/day, gradually decreasing the dose) and folic acid 5 mg/day were administered. During the treatment, symptoms significantly improved, haemoglobin increased from 13 g/dL to 15 g/dL, haematocrit increased from 38.7% to 43.9%; glycaemia was normal during corticosteroid therapy. Evolution of haematological parameters during the treatment is presented in Table I.

Table I
Haematological parameters during treatment

	Initial value	On Methimazole	On Corticosteroids	Final value
Haemoglobin (g/dL)	14.7	13.3	13	15
Haematocrit (%)	41.9	38.7	39.3	43.9
Reticulocytes (%)	-	2.8%	3.1%	-
LDH (IU/L)	-	164	180	-
TGO/TGP (IU/L)	21/36	17/28	22/67	20/21

It was registered a gradual decrease up to normalization of both total bilirubin (3.62 → 1.59 → 1.07 mg/dL) and unconjugated bilirubin (2.82 → 0.96 → 0.75 mg/dL) – (Figure 2).

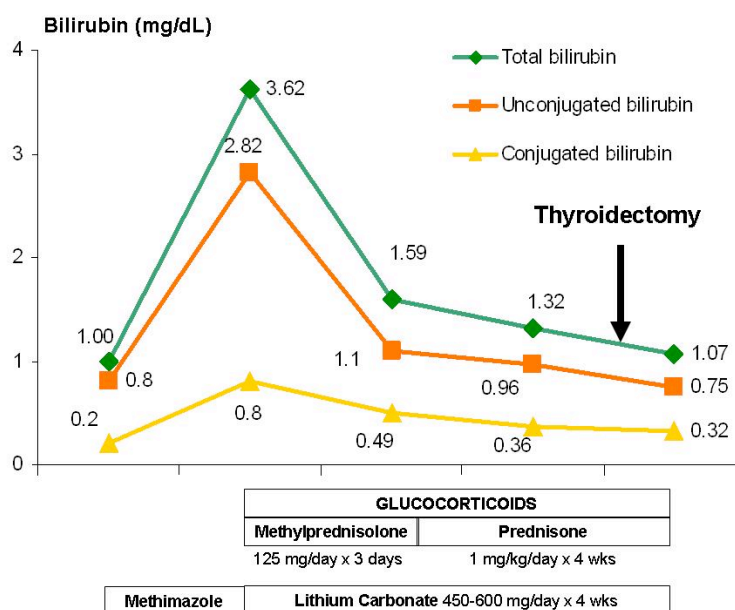


Figure 2.
Evolution of bilirubin on treatment

After normalization of thyroid hormones, total thyroidectomy was safely performed and the patient had an uneventful recovery. Postoperatively, levothyroxine replacement therapy (100 µg/day) was initiated, with maintenance of TSH in the normal range.

Common and typical adverse reactions of antithyroid drugs include dose dependent hypothyroidism, pruritus and rash, mild dose dependent neutropenia. Rare severe side effects were: allergy-mediated agranulocytosis, aplastic anaemia, asymptomatic transient increase in liver enzymes or severe, even lethal liver injury of cholestatic or hepatocellular pattern [6, 24].

Anaemia could be present in up to 41.6% of men with Graves' disease, more frequent as compared with women (17.5%), but it corrects with normalization of thyroid function [10]; rare cases presented with autoimmune haemolytic anaemia [22] or pancytopenia [1, 17]. However, our patient initially presented without anaemia.

After 2 weeks of Methimazole 30 mg/day, the patient presented with pruritus, scleral jaundice and arthralgias. Because arthralgia could be related to more serious immune side effects [24], it was mandatory to stop the antithyroid drug therapy in this case. It is already known that methimazole-induced agranulocytosis with or without neutropenia occurred more frequently on 30 mg daily than on 15 mg daily [27]. However, in our patient, a starting dose of 30 mg Methimazole was justified by the severity of hyperthyroidism.

Haematological assessment revealed in our case mild anaemia. Thrombocytes were normal ($165,000/\text{mm}^3$), coagulation tests (INR, APTT) were normal, excluding Evans' syndrome, in which autoimmune haemolytic anaemia and idiopathic thrombocytopenic *purpura* occur [29, 35]. Methimazole could induce mainly aplastic anaemia [12, 19, 28, 32], and rarely haemolytic anaemia [4, 25]. Methimazole-induced aplastic anaemia was reported to occur not only at the first exposure, but also at the third drug's exposure [20]. Despite the clinical and laboratory severity of antithyroid drug-associated aplasia, the prognosis and short term course was good [3]. Also propylthiouracil was cited to induce haemolytic anaemia [15].

The mechanisms implied in haemolytic anaemia induced by carbimazole are autoimmune and therefore incompletely understood. Carbimazole-dependent antibodies against erythrocytes were detected in some cases [4, 25]. Some of these were directed against the proteins of the Rh complex. One reported patient presented with haemolytic anaemia, neutropenia and mild thrombocytopenia. He presented carbimazole-dependent antibodies against platelet endothelial cell adhesion molecule 1 (PECAM-1). These antibodies could also be detected in serum of patients with haemolytic anaemia and normal leucocytes and platelets. The authors assumed that carbimazole can induce drug-dependent antibodies against erythrocytes that cause anaemia and also drug-dependent antibodies against the widely expressed PECAM-1, that cause mild cytopenia [4]. Drug-induced autoimmune and non-autoimmune thrombocytopenia was also reported for heparin [30].

Corticosteroids were effective and well tolerated in our case; despite impact of short and medium-term glucocorticoid treatment on glucose homeostasis [7], corticosteroids had no effect on glucose metabolism in this thyrotoxic patient, probably due to normal endogenous β -cell reserve.

Apart glucocorticoids, lithium carbonate has multiple effects on thyroid hormones' levels: it decreases thyroid hormone release and peripheral deiodination of thyroxine by decreasing the activity of 5' de-

iodinase type I [13]. Because its' important antithyroid activity, lithium is a second choice drug (after methimazole and propylthiouracil) in the medical treatment of thyrotoxicosis [2, 9, 16]. This is the reason for choosing lithium carbonate for thyrotoxicosis' treatment in our case. Lithium also increases radioiodine retention in the thyroid, so adjuvant lithium also improves the efficacy of radioiodine in the treatment of hyperthyroidism, both in Graves' disease and toxic nodular goiter [18]. In euthyroid patients treated with lithium for bipolar disorder, goiter developed in up to 40% of cases and hypothyroidism in 20% [16]. On the other hand, lithium-induced hyperthyroidism can also occur, representing around 0.7% of all causes of hyperthyroidism in a published series [5]. Fortunately, lithium treatment was able to normalize thyroid hormones levels in our patient before radical therapy, preventing serious complications such as thyroid storm after thyroidectomy.

Conclusions

This is the first case report of haemolytic anaemia associated with Methimazole in Romania. It should be underlined that haemolytic anaemia may be a rare side effect associated with methimazole therapy. Careful follow-up of patients treated with Methimazole is mandatory, especially on blood cells' lines and liver function tests. Precocious diagnosis and multidisciplinary (*endocrinologist, haematologist, endocrine surgeon*) team approach are mandatory for correct treatment and favourable prognosis in such patients.

References

1. Akoum R, Michel S, Wafic T, Emile B, Marwan M, Khaled H, Gerard A. Myelodysplastic syndrome and pancytopenia responding to treatment of hyperthyroidism: peripheral blood and bone marrow analysis before and after antihormonal treatment. *J Cancer Res Ther.* 2007; 3(1): 43-46.
2. Barbesino G. Drugs affecting thyroid function. *Thyroid.* 2010; 20(7): 763-770.
3. Biswas N, Ahn YH, Goldman JM, Schwartz JM. Aplastic anemia associated with antithyroid drugs. *Am J Med Sci.* 1991; 301(3): 190-194.
4. Bux J, Ernst-Schlegel M, Rothe B, Panzer C. Neutropenia and anaemia due to carbimazole-dependent antibodies. *Br J Haematol.* 2000; 109(1): 243-247.
5. Carle A, Pedersen IB, Knudsen N, Perrild H, Ovesen L, Rasmussen LB, Laurberg P. Epidemiology of subtypes of hyperthyroidism in Denmark: a population-based study. *Eur J Endocrinol.* 2011; 164(5): 801-809.
6. Cooper DS. Antithyroid drugs. *N Engl J Med.* 2005; 352(9): 905-917.
7. Negres S., Chirita C., Morosan E., Arsene A.L., Experimental pharmacological model of diabetes induction with aloxan in rat. *Farmacia,* 2013; 61(2): 313-322.
8. Danciulescu MR, Carsote M, Trifanescu R, Ferehide D, Poiana C. Antithyroid drugs induced agranulocytosis and multiple myeloma: case report and general considerations. *J Med Life.* 2013; 6(3): 327-331.

9. Fumarola A, Di FA, Dainelli M, Grani G, Calvanese A. Medical treatment of hyperthyroidism: state of the art. *Exp Clin Endocrinol Diabetes*. 2010; 118(10): 678-684.
10. Gianoukakis AG, Leigh MJ, Richards P, Christenson PD, Hakimian A, Fu P, Nihara Y, Smith TJ. Characterization of the anaemia associated with Graves' disease. *Clin Endocrinol (Oxf)*. 2009; 70(5): 781-787.
11. Hamerschlak N, Maluf E, Biasi CA, Avezum JA, Eluf-Neto J, Passeto FR, Lorand-Metze IG, Goldenberg D, Leite SC, de Oliveira Werneck RD, Nascimento da Motta PL, Oliveira de Miranda CE, Tostes Pintao MC, Moraes de SH, Borbolla JR, Pasquini R. Incidence and risk factors for agranulocytosis in Latin American countries--the Latin Study: a multicenter study. *Eur J Clin Pharmacol*. 2008; 64(9): 921-929.
12. Jakucs J., Pocsay G. Successful treatment of methimazole-induced severe aplastic anemia with recombinant human granulocyte colony-stimulating factor and high-dosage steroids. *J Endocrinol Invest*. 2006; 29(1): 74-77.
13. Kibirige D, Luzinda K, Ssekitoleso R. Spectrum of lithium induced thyroid abnormalities: a current perspective. *Thyroid Res*. 2013; 6(1): 3.
14. Kimura M, Seki T, Ozawa H, Ishihara T, Komatsu M, Tajiri S, Yanagi H, Nishina M, Noh JY, Fukagawa M, Takagi A. The onset of antineutrophil cytoplasmic antibody-associated vasculitis immediately after methimazole was switched to propylthiouracil in a woman with Graves' disease who wished to become pregnant. *Endocr J*. 2013; 60(3): 383-388.
15. Kuo CS, Lin JS, Lin HD. Propylthiouracil-induced hemolytic anemia. *Zhonghua Yi Xue Za Zhi (Taipei)*. 2001; 64(12): 735-738.
16. Lazarus JH. Lithium and thyroid. *Best Pract Res Clin Endocrinol Metab*. 2009; 23(6): 723-733.
17. Lima CS, Zantut Wittmann DE, Castro V, Tambascia MA, Lorand-Metze I, Saad ST, Costa FF. Pancytopenia in untreated patients with Graves' disease. *Thyroid*. 2006; 16(4): 403-409.
18. Martin NM, Patel M, Nijher GM, Misra S, Murphy E, Meeran K. Adjuvant lithium improves the efficacy of radioactive iodine treatment in Graves' and toxic nodular disease. *Clin Endocrinol (Oxf)*. 2012; 77(4): 621-627.
19. Mechelli S, Bolognesi S, Siuti E, Stefanelli A, Castiglioni MG. Methimazole-induced aplastic anemia. *Recenti Prog Med*. 1999; 90(9): 470-472.
20. Mezquita P, Luna V, Munoz-Torres M, Torres-Vela E, Lopez-Rodriguez F, Callejas JL, Escobar-Jimenez F. Methimazole-induced aplastic anemia in third exposure: successful treatment with recombinant human granulocyte colony-stimulating factor. *Thyroid*. 1998; 8(9): 791-794.
21. Mutharasan P, Oatis W, Kwaan H, Molitch M. Delayed antithyroid drug-induced agranulocytosis. *Endocr Pract*. 2012; 18(4): e69-e72.
22. Ogihara T, Katoh H, Yoshitake H, Iyori S, Saito I. Hyperthyroidism associated with autoimmune hemolytic anemia and periodic paralysis: a report of a case in which antihyperthyroid therapy alone was effective against hemolysis. *Jpn J Med*. 1987; 26(3): 401-403.
23. Otsuka F, Noh JY, Chino T, Shimizu T, Mukasa K, Ito K, Ito K, Taniyama M. Hepatotoxicity and cutaneous reactions after antithyroid drug administration. *Clin Endocrinol (Oxf)*. 2012; 77(2): 310-315.
24. Perger L, Burgi U, Fattinger K. [Pharmacotherapy of hyperthyreosis--adverse drug reactions]. *Ther Umsch*. 2011; 68(6): 303-308.
25. Salama A, Northoff H, Burkhardt H, Mueller-Eckhardt C. Carbimazole-induced immune haemolytic anaemia: role of drug-red blood cell complexes for immunization. *Br J Haematol*. 1988; 68(4): 479-482.
26. Tajiri J. Issues of side effects induced by antithyroid drugs. *Nihon Rinsho*. 2006; 64(12): 2251-2256.
27. Takata K, Kubota S, Fukata S, Kudo T, Nishihara E, Ito M, Amino N, Miyauchi A. Methimazole-induced agranulocytosis in patients with Graves' disease is more frequent with an initial dose of 30 mg daily than with 15 mg daily. *Thyroid*. 2009; 19(6): 559-563.

28. Thomas D, Moisisidis A, Tsiakalos A, Alexandraki K, Syriou V, Kaltsas G. Antithyroid drug-induced aplastic anemia. *Thyroid*. 2008; 18(10): 1043-1048.
29. Ushiki T, Masuko M, Nikkuni K, Terukina-Yoshida J, Momotsu-Nanba A, Morikawa H, Usami A, Fuse I, Toba K, Takai K, Aizawa Y. Successful remission of Evans syndrome associated with Graves' disease by using propylthiouracil monotherapy. *Intern Med*. 2011; 50(6): 621-625.
30. Voican I, Onisai M, Nicolescu A, Vladareanu AM, Vladareanu R. Heparin induced thrombocytopenia: a review. *Farmacia*. 2012; 60(6): 773-784.
31. Watanabe N, Narimatsu H, Noh JY, Yamaguchi T, Kobayashi K, Kami M, Kunii Y, Mukasa K, Ito K, Ito K. Antithyroid drug-induced hematopoietic damage: a retrospective cohort study of agranulocytosis and pancytopenia involving 50,385 patients with Graves' disease. *J Clin Endocrinol Metab*. 2012;97(1):E49-E53.
32. Yamamoto A, Katayama Y, Tomiyama K, Hosoi H, Hirata F, Kimura F, Fujita K, Yasuda H. Methimazole-induced aplastic anemia caused by hypocellular bone marrow with plasmacytosis. *Thyroid*. 2004; 14(3): 231-235.
33. Yang J, Zhong J, Zhou LZ, Hong T, Xiao XH, Wen GB. Sudden onset agranulocytosis and hepatotoxicity after taking methimazole. *Intern Med*. 2012; 51(16): 2189-2192.
34. Yang J, Zhong J, Xiao XH, Zhou LZ, Chen YJ, Liu JH, Cao RX, Wen GB. The relationship between bone marrow characteristics and the clinical prognosis of antithyroid drug-induced agranulocytosis. *Endocr J*. 2013; 60(2): 185-189.
35. Yashiro M, Nagoshi H, Kasuga Y, Isobe H, Kitajima S, Nakagawa T, Ohshima J, Ide K, Someya K, Saito N. Evans' syndrome associated with Graves' disease. *Intern Med*. 1996; 35(12): 987-990.
36. Yasude T, Kishida D, Tazawa K, Matsuda M, Ishii W, Yazaki M, Ikeda S. ANCA-associated vasculitis with central retinal artery occlusion developing during treatment with methimazole. *Intern Med*. 2012; 51(22): 3177-3180.

Manuscript received: September 4th 2013